

Vertical Reduction Mammoplasty: Medial Versus Inferior Pedicle

SHERINE M. ABOUL FOTOUH, M.D.; BASIM M. ZAKI, M.D.; AHMED M. ABOUL WAFA, M.D. and MOSTAFA AWAD, M.D.

The Department of Plastic Surgery, Faculty of Medicine, Ain Shams University.

ABSTRACT

Successful aesthetic outcomes of breast reduction operations depend on the surgeon's understanding of the available techniques.

In this study, comparison between breast reduction using medial pedicle (20 breasts-10 patients) and breast reduction using inferior pedicle (20 breasts-10 patients) both adapted for vertical skin closure was done. Points of comparison were: Amount of breast tissue reduction, length of vertical scar, both early and later maintenance of breast shape, operative time, complications, and overall patients' satisfaction. Regarding patients' satisfaction and complication rates, there was no significant difference between the 2 groups. Although, medial pedicle technique allowed less amount of breast tissue reduction, longer vertical scar and early over-projecting and inferiorly flattened contour, it provided shorter operative time and more improved long term shape retention. While inferior pedicle technique allowed more amount of breast tissue reduction, shorter vertical scar and early natural breast contour, but it provided longer operative time and inevitable later bottoming out.

INTRODUCTION

Clear understanding of the blood supply of the breast led to the development of pedicle techniques and achievement of reliable circulation to the nipple-areola complex (NAC) in breast reduction surgery [1]. Pedicle types include central [2], medial [3,4], lateral [5], superior [6], bipedicle [4,7] and inferior [8-11]. These pedicles are either dermal or glandular according to the orientation of the major vascular supply of the NAC. Medial, lateral, transverse bipedicle and superior pedicles are dermal pedicles while central, vertical bipedicle and inferior pedicles are glandular pedicles [12]. The preservation of the dermis in glandular pedicle techniques is not crucial for the NAC safety [2,7,13,14]. However, preservation of 1-2cm of circum-areolar dermis is recommended not to compromise the local circulatory pathways (arterial and venous) about the areolar margin [12,13]. The inferior pedicle technique proved to be safe, reproducible and relatively easy to teach. Sensation was mostly preserved and lactation was certainly possible [15].

It became the most favored approach to breast reduction surgery among plastic surgeons during the 1980s and 1990s [16,17]. The development of some drawbacks such as: boxy shape, later bottoming out with extensive scarring stayed issues that couldn't always be solved [15]. The inferior pedicle and other pedicle techniques were adapted for inverted T skin closure with its undesirable extensive scarring. This encouraged the development of shorter scar techniques precluding the concept of the skin brassiere as holding breast shape [18]. Various pedicles were adapted to vertical scar only [15,16,19,20] or with small inframammary extension [19,21,22]. Benelli [23] described a periareolar technique with superior pedicle, while Hammond [24] used the same scar with vertical extension with inferior pedicle. Annular breast tissue reduction through an inframammary incision was an interesting short scar technique by Corduff and Taylor [25]. However, The results of breast reductions over 1000g were less predictable with short scar techniques [26,27].

Although, many surgeons quite correctly, use different breast reduction techniques, many continue to claim a universal application for their favored method. Vertical mammoplasty with medial pedicle as described by Findlay [16] and adopted by many surgeons provided reduced scarring, improved and maintained contour, comparable nipple sensation as well as surgeons' and patients' satisfaction. But in larger reductions when safety is the main concern [26,27], in narrow based breasts [27] and in revisions of inferior pedicle breast reductions [15,16], inferior pedicle technique must be considered.

In this study, a comparison was performed between medial pedicle and inferior pedicle breast reductions both adapted for vertical skin closure using the same skin markings as proposed by Findlay [15]. An anchor stitch for the inferior pedicle similar to Eed fixation stitch [28] was used as an attempt to avoid later bottoming out.

PATIENTS AND METHODS

The study was conducted on a total of 20 patients, ranging in age from 18-42 years, with macromastia during the period from January 2003-March 2005. All patients shared the common complaint of cosmetic disfigurement, heavy breasts and shoulder pain. The patients were divided according to the pedicle used into two groups:

Group I: (10 patients-20 breasts): Medial pedicle.

Group II: (10 patients-20 breasts): Inferior pedicle.

The skin excision in the two groups was designed for vertical closure.

The skin markings were done with the patient standing. The breast meridian was first marked and the upper border of the opening of the new areola (A) was determined on the meridian at a level of 1-2cm below the level of the inframammary crease (Fig. 1). Point B corresponded to the mid-inframammary crease. Point C was determined 3-5cm above point B on a line connecting point B to the nipple (in such cases when there was no significant nipple divergence or convergence). Points A and C are connected medially and laterally by curved lines to include within them the proposed skin excision. On the cephalic ends of the curved lines a mosque shaped dome is designed (8cms each limb) to accommodate a 5cm diameter areola as noted previously by LeJour [20].

The Medial Pedicle (Fig. 2):

The design was similar to that of Findlay [15,16]. Half the base width was designed in the new areola site within the "mosque shaped dome", whereas the base varied from 6-8cms reaching up to 10cms for longer pedicles. A rim of tissue extending 1.5cm beyond the areola was left for safety. Before de-epithelialization of the pedicle, the expected breast tissue to be excised is infiltrated with around 150-200ml saline adrenaline (1:200,000). Incision of the pedicle is carried out with care to avoid any undermining. The remaining skin and breast tissue is resected wholesome with some lateral beveling. Adequate subcutaneous tissue was removed towards the inframammary fold so as to reduce breast fullness and ensure skin retraction. The pedicle was rotated and sutured at the cephalic apex of the areolar opening and another stay suture was taken at its lower end. The breast size was assessed for the possibility of resection of additional tissues if required. No pectoralis fascia sutures were employed. The medial and lateral pillars were then sutured together starting at an inferior and deeper level progressing upwards and superficially similar

to the technique described by LeJour [20]. The dermal layer was closed with interrupted inverted sutures followed by a continuous subcuticular suture gathering the skin upwards. The areola was closed with a few interrupted deep dermal sutures followed by subcuticular sutures. Suction drains were used routinely. A surgical brassiere was applied.

The Inferior Pedicle (Fig. 3):

The pedicle was the dermoglandular pyramidal flap described by many authors [8-11]. On marking, the width of the pedicle along the inframammary fold was 8-10cm with its mid-point at B the base of the pedicle was dotted in the area between B and C points. A rim of tissue (1cm) was left around the areola.

Saline-adrenaline (1/200,000) was infiltrated in the proposed resection areas. The pedicle above point C was deepithelialized while the lower part (between B and C) was freed by subcutaneous dissection leaving very thin layer of fat with the overlying skin. Creation of the pedicle was followed by resection of the surrounding glandular tissue with its skin as marked. Inner beveling during glandular excision was performed especially on the lateral side. The pectoralis fascia was exposed at the level of the second intercostal space near the midline. A heavy 2/0 PDS stitch was taken in the muscle at that point then passed through the pedicle at the junction between the dermis and the glandular tissue (corresponding to point C) and back through the pedicle again at a point 1cm cephalic to the stitch outlet (Fig. 4). The stitch then was tied up loosely taking care not to kink the pedicle. The idea of that stitch was to prevent inferior fullness and allowing the folding of the pedicle behind the NAC adding to projection and possibly prevent later bottoming. The NAC was inserted in its new position. At this stage, the medial and lateral pillars were brought together and closure was carried out as in medial pedicle technique.

RESULTS

The first group (20 breasts) was operated upon by a medial pedicle reduction mammoplasty with 400-800g (average 580g) reduction. The second group (20 patients) was operated upon by an inferior pedicle reduction mammoplasty with 400-1100g (average 650g) reduction (Table 1).

Congestion of the NAC of one breast (5%) in the second group was noticed after skin closure. Anchor stitch removal relieved the congestion with no significant asymmetry noticed later on in the follow up.

The length of the vertical scar at the end of the operation was 10-14cm (average 13cm) in the first group compared to 8-12cm (average 11cm) in the second group.

The initial shape of the breasts in the medial pedicle group showed exaggerated projection, superior fullness and inferior flattening. The inferior pedicle group had better natural contour with satisfactory projection and less inferior flattening.

The average operative time noted was 3 hours in the first group as compared to 4 hours in the second group.

Vertical wound disruption of 1.5cm occurred in one breast (5%) of the first group and required no extra-time for complete healing.

Complete loss of nipple sensation was noted in one breast (5%) within the first group. Partial recovery took place after a year.

Seroma occurred bilaterally in the first two patients (4 breasts) (20%) of the second group.

Evacuation, dressing and taping allowed complete healing within 3 weeks.

Settling down of the breast shape in the medial pedicle group took 2-3 weeks in small reductions (400-600g) and up to 5 weeks in the larger reductions (650-800g). After settling down, the superior fullness, the inferior flattening and projection decreased leaving aesthetically pleasing breast contour.

Touch up for bilateral dog ears by simple excision was required in one patient 3 months postoperatively.

Late follow up; 6-24 months postoperatively, revealed either no (6 patients) or minimal (4 patients) bottoming out in the medial pedicle group while all patients of the inferior pedicle group showed mild bottoming.

The patients of both groups (Figs. 5,6) were satisfied by the breast contour which overcame the complaint of 2 patients of the medial pedicle group claiming inadequate reduction. None of the patients requested a secondary reduction.

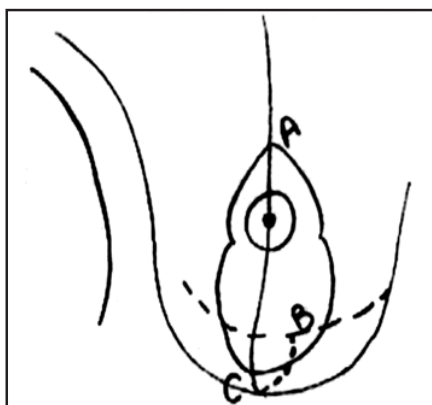


Fig. (1): Preoperative skin markings: A, The level of the upper border of the new areola 1-2cm below inframammary level. B, Mid-inframammary crease. C, 3-5cm above B on the breast meridian.

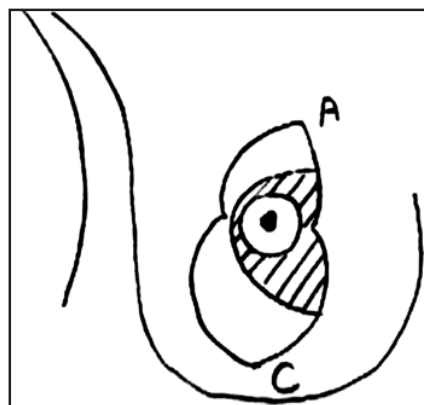


Fig. (2): Skin markings of medial pedicle with vertical skin excision. Findlay (2002).

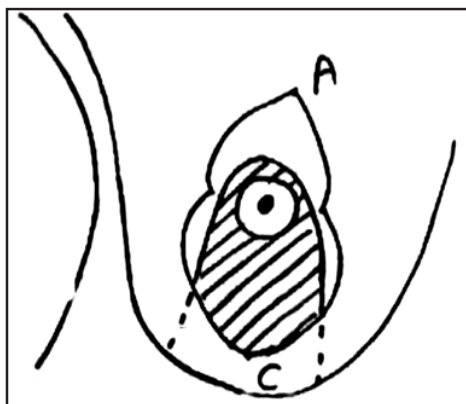


Fig. (3): Skin markings of inferior pedicle with vertical skin excision. Findlay (2002)

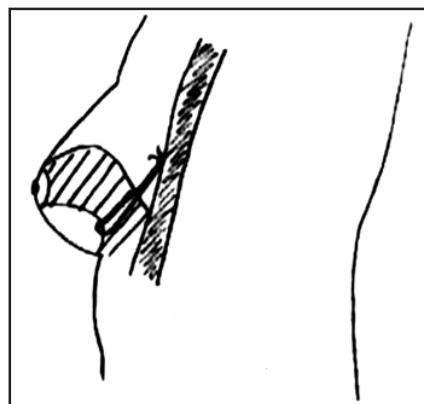


Fig. (4): Lateral view of inferior pedicle showing the anchor stitch.

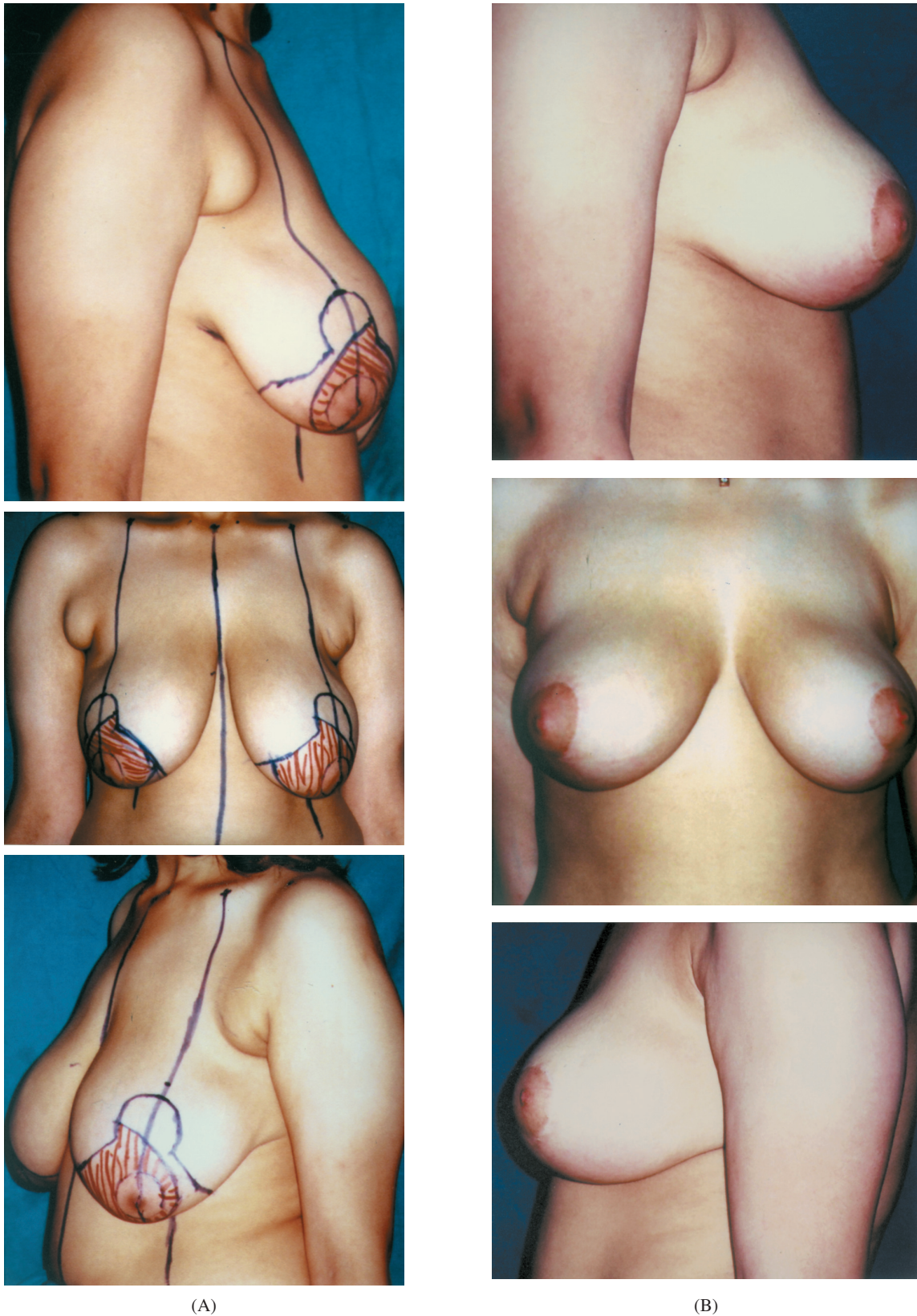


Fig. (5): Vertical mammaplasty using medial pedicle: A; Preoperative right lateral, front and left lateral views. B; Postoperative right lateral, front and left lateral views.

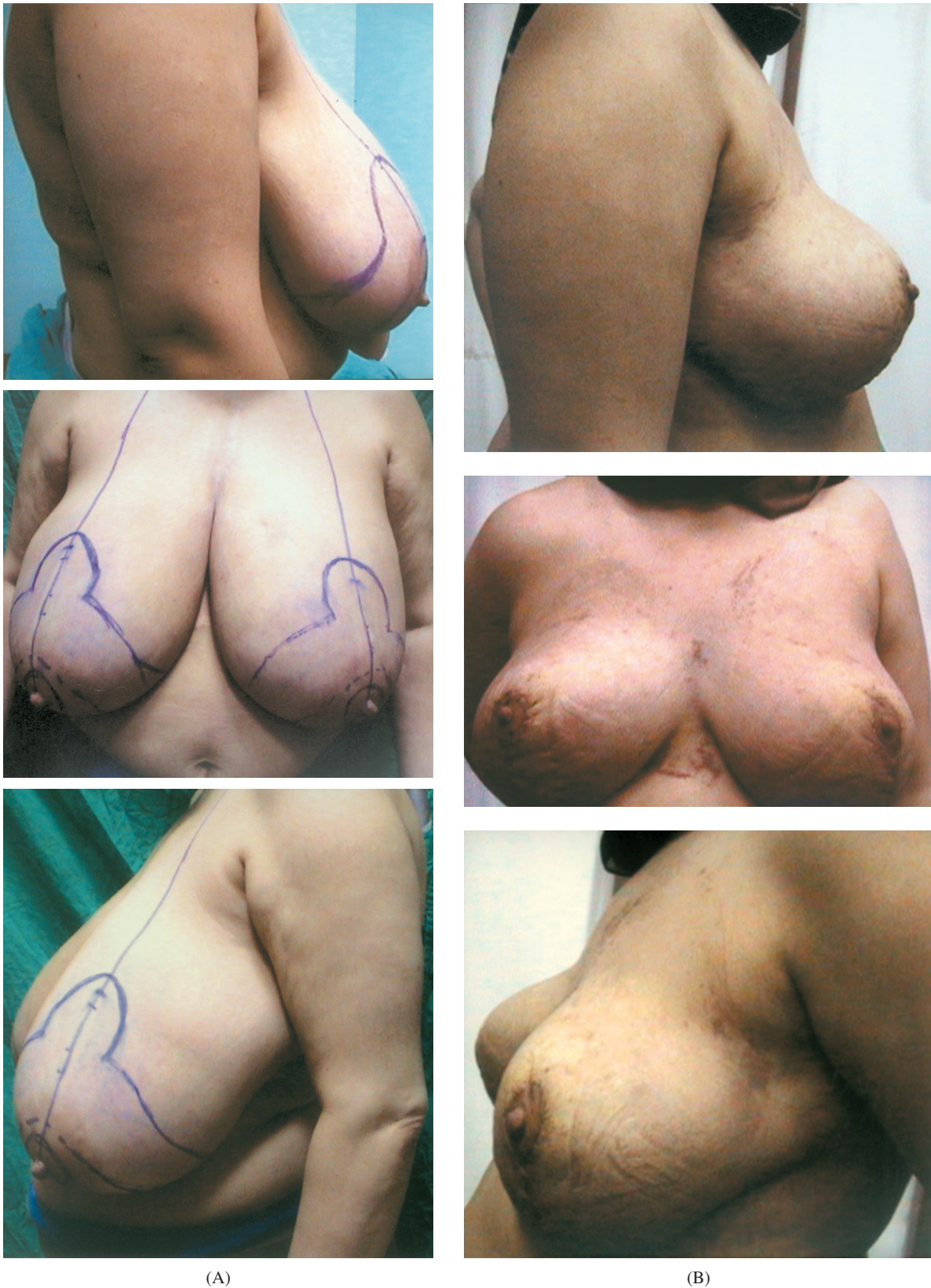

Fig. (6): Vertical mammaplasty using inferior pedicle: A; Preoperative right lateral, front and left lateral views. B; Postoperative right lateral, front and left lateral views.

Table (1): Comparison between the results of the 2 groups.

Points of comparison	Medial pedicle group (10 patients-20 breasts)	Inferior pedicle group (10 patients-20 breasts)
Amount of reduction	400-800g (average 580g)	400-1100g (average 650g)
Length of vertical skin closure	10-14cm (average 13cm)	8-12cm (average 11cm)
Initial breast shape	Exaggerated projection, superior fullness and inferior flattening	Better contour with good projection and less inferior flattening
Operative time	Average 3hs	Average 4hs
Wound disruption	1 breast (5%)	–
Seroma	–	4 breasts
Loss of nipple sensation	1 breast (5%)	–
Later bottoming	8 breasts showed very mild bottoming (40%)	All patients showed mild bottoming (100%)
Touch up	2 breasts (10%) needed dog ear excision	–

DISCUSSION

There are many different techniques for performing breast reduction, yet there is no ideal one so far [15]. On the other hand each surgeon has to master more than one technique to fit the different patient's priorities and clinical situations [26].

Medial pedicle technique with vertical skin closure described by Findlay achieved shorter scar and better long term breast shape [15,16,30]. The unparalleled safety of the inferior pedicle technique put it in the armamentarium of most breast reduction surgeons.

In this study a comparison between the results of the medial pedicle and the inferior pedicle (using an anchor stitch) breast reduction with vertical skin closure was done.

The amount of breast tissue reduction in the medial pedicle technique was 400-800g (average 580g), while in the inferior pedicle technique, 400-1100g (average 650g) was removed. Although the difference in the excised amount was not significant, yet, clinically the inferior pedicle technique allowed for more areas of reduction. The medial pedicle by Findlay is a full thickness dermoglandular pedicle that is adherent to the chest wall allowing no medial reduction or pedicle thickness trimming. In addition, the art of the technique depends on limited superior excision. All of this makes the inferior pedicle more suitable for larger breast reductions.

The use of the anchor stitch by many surgeons in different pedicles was reported [20,28,29]. The literature lacks the precise leveling of the anchor

stitch especially in the inferior pedicle [28,29]. Placing the anchor stitch at the level of the proposed inframammary fold decreased the inferior fullness and inferior migration (bottoming out) of the breast parenchyma. On the contrary, the stitch caused the pedicle to be folded behind the NAC adding to the projection [29].

Congestion of the NAC after taking the anchor stitch was noticed in one breast of the inferior pedicle group. Improvement occurred after removal of the stitch with no later significant asymmetry between the two breasts. The anchor stitch in all patients was vertically oriented and loosely tied so as not to interfere with the vertically directed intercostals perforators of the inferior pedicle. However, it may theoretically violate one of the perforators acting as a factor impairing the blood supply with actual clinical complications if other factors are involved. On anchorage of the inferior pedicle by the stitch, a small secondary dead space away from the negative suction of the drains was formed between the skin flap and the lower end of the pedicle (Fig. 4) resulting in a small seroma formation in the first two patients of this group. Firm postoperative taping of the lower pole of the breast helped eliminating this problem in the consequent 8 patients.

Dissection of the inferior pedicle took more operative time than that for the medial pedicle. The difference in the total operative time was about one hour.

At the end of the operation, the length of the vertical skin closure was shorter with less skin gathering in the inferior pedicle technique. Relative

inferior fullness and the availability of translating the excess vertical skin component to the periareolar component helped in shortening the length of the vertical skin closure and later scarring.

The initial breast shape and contour of the medial pedicle group showed exaggerated projection, exaggerated superior fullness and inferior flattening. Many surgeons obviated the use of this technique because of this unnatural postoperative breast appearance [15,16,30]. The inferior pedicle group showed more natural and pleasing contour with adequate projection and relative inferior fullness.

Nipple sensitivity to touch was lost completely unilaterally in one patient of the medial pedicle group. Partial recovery was noted after a year's follow up. The relative retention of sensation in the medial pedicle group and complete retention of sensation in the inferior pedicle group made them comparable.

Later bottoming out of the breast or pseudoptosis was considered an inevitable sequel of the inferior pedicle technique [15,16,29,30]. Different causes of bottoming out were proposed; relying on the skin to hold the shape especially if the skin is under tension or previously damaged [29], the weight of tissue left (inadequate reduction), leaving tissues where gravity maximally works (inferior pole) [15,16,30]. Avoiding bottoming out was tried through; adequate reduction, the use of anchor stitch, vertical skin excision and tension free closure. In the inferior pedicle group mild bottoming out occurred in all patients as compared to the minimal bottoming out in only four patients of the medial pedicle group.

Despite the settling down of the breast shape in the medial pedicle group within 2-5 weeks, excess skin at the lower end of the vertical scar occurred in one patient requiring surgical revision 3 months postoperatively.

Both techniques achieved adequate patients' satisfaction with minimal complications.

The medial pedicle technique was superior in maintenance of the pleasant breast contour making it as an excellent choice for most of the breast reductions. But it had the limitation of inadequate reduction in larger breasts.

Severe macromastia, narrow based breast, and previously reduced breast with inferior pedicle technique are relative indications to the use of the inferior pedicle modification. This keeps the inferior

pedicle technique as a reproducible procedure for breast reduction by combining it to the vertical skin closure group. Although the bottoming out of the breast in the inferior pedicle group was inevitable, it could be decreased to the least by adequate reduction, anchor stitching in addition to the vertical skin closure instead of the inverted T skin closure.

REFERENCES

- 1- Lexer E.: Hypertrophie beider mamae. *Munchen Med. Wochenschr.*, 59: 1702, 1912. Quoted after: Daane S.P. and Rockwell W.B.: Breast reduction techniques and outcomes: A meta-analysis. *Aesthetic Surg. J.*, 19: 293, 1999.
- 2- Biesenberger H.: Fine neue methods der mammaplastik. *Zentralbl. Chir.*, 55: 2382, 1928. Quoted after: White D.J. and Maxwell G.P.: Breast reduction In: Achauer B.M., Eriksson E., Guyuron B., Coleman I.J., Russell R.C. and Vander Kolk C.A. (editors). *Plastic surgery; indications, operations, and outcomes*. St. Louis. London. Philadelphia. Sydney. Toronto. Mosby, Inc., 149, 2705, 2000.
- 3- Schwartzmann E.: Avoidance of nipple necrosis by preservation of corium in one stage plastic surgery of the breast. *Rev. Chir. Struct.*, 9: 206, 1937.
- 4- Strombeck J.O.: Mammaplasty: Report of a new technique based on the two pedicle procedure. *Br. J. Plast. Surg.*, 13: 79, 1960.
- 5- Skoog T.: A technique of breast reduction-transposition of the nipple on a cutaneous vascular pedicle. *Acta Chir. Scand.*, 126: 453, 1963.
- 6- Pitanguy I.: Surgical correction of breast hypertrophy. *Br. J. Plast. Surg.*, 20: 78, 1967.
- 7- McKissock P.K.: Reduction mammaplasty with a vertical dermal flap. *Plast. Reconstr. Surg.*, 49: 245, 1972.
- 8- Ribeiro L.: A new technique for reduction mammaplasty. *Plast. Reconstr. Surg.*, 55: 330, 1975.
- 9- Robbins T.H.: A reduction mammaplasty with the areola nipple based on an inferior pedicle. *Plast. Reconstr. Surg.*, 59: 64, 1977.
- 10- Courtiss E.H. and Goldwyn R.M.: Reduction mammaplasty by the inferior pedicle technique: An alternative to free nipple and areola grafting for severe macromastia or extreme ptosis. *Plast. Reconstr. Surg.*, 59: 500, 1977.
- 11- Georgiade N.G., Serafin D., Morris R. and Georgiade G.: Reduction mammaplasty utilizing an inferior pedicle nipple areolar flap. *Ann. Plast. Surg.*, 3: 211, 1979.
- 12- Hall-Findlay E.J.: Breast reduction. In: McCarthy J.G., Galiano R.D. and Boutros S.G. (eds.). *Current therapy in Plastic Surgery*. Philadelphia, Saunders, p: 403, 2006.
- 13- Climo M.S. and Alexander J.E.: Intercostothelial circulation: Nipple survival in reduction mammaplasty in the absence of a dermal pedicle. *Ann. Plast. Surg.*, 4: 128, 1980.
- 14- Kroll S.S.: A comparison of deepithelialization and de-skinning in inferior pedicle breast reduction. *Plast. Reconstr. Surg.*, 81: 913, 1988.
- 15- Hall-Findlay E.J.: Pedicles in vertical reduction and mastopexy. *Clin. Plastic Surg.*, 29: 379, 2002.

- 16- Hall-Findlay E.J.: A simplified vertical reduction mammoplasty: shortening of learning curve. *Plast. Reconstr. Surg.*, 104: 748, 1999.
- 17- Daane S.P. and Rockwell W.B.: Breast reduction technique and outcomes: A meta-analysis. *Aesthetic Surg. J.*, 19: 293, 1999.
- 18- Wise R.J.: A preliminary report on a method of planning the mammoplasty. *Plast. Reconstr. Surg.*, 17: 367, 1956.
- 19- Lassus C.: A technique for breast reduction. *Int. Surg.*, 53: 69, 1970.
- 20- Lejour M.: Vertical mammoplasty and liposuction of the breast. *Plast. Reconstr. Surg.*, 94: 100, 1994.
- 21- Marchac D. and de Olarte G.: Reduction mammoplasty and correction of ptosis with a short inframammary scar. *Plast. Reconstr. Surg.*, 69: 45, 1982.
- 22- Ramirez O.M.: Reduction mammoplasty with the Owl incision and no undermining. *Plast. Reconstr. Surg.*, 109: 512, 2002.
- 23- Benelli L.: A new periareolar mammoplasty: The round block technique. *Aesthetic Plast. Surg.*, 14: 93, 1990.
- 24- Hammond D.C.: Short scar periareolar inferior pedicle reduction (SPAIR) mammoplasty. *Plast. Reconstr. Surg.*, 103: 890, 1999.
- 25- Corduff N. and Taylor G.I.: Subglandular breast reduction: The evolution of a minimal scar approach to breast reduction. *Plast. Reconstr. Surg.*, 113: 175, 2004.
- 26- McCully S.J. and Hudson D.A.: Short-scar breast reduction: Why all the fuss? *Plast. Reconstr. Surg.*, 107: 965, 2001.
- 27- Beer G.M., Spicher I., Cierpka K.A. and Meyer V.E.: Benefits and pitfalls of vertical scar breast reduction. *Br. J. Plast. Surg.*, 57: 12, 2004.
- 28- Eed M.D.A.: A new personal procedure for breast reduction and lifting. *Aesthetic Plast. Surg.*, 24: 206, 2000.
- 29- Reus W.F. and Mathes S.J.: Preservation of projection after reduction mammoplasty: Long-term follow-up of the inferior pedicle technique. *Plast. Reconstr. Surg.*, 82: 644, 1987.
- 30- Karp N.S.: Medial pedicle/vertical breast reduction made easy, the importance of complete inferior glandular resection. *Ann. Plast. Surg.*, 52: 458, 2004.